

Assessment of corneal endothelial cell morphology and anterior segment parameters in COVID-19

Burak Oren and Dilara Ozkoyuncu Kocabas 

Ther Adv Ophthalmol

2022, Vol. 14: 1–9

DOI: 10.1177/
25158414221096057

© The Author(s), 2022.
Article reuse guidelines:
[sagepub.com/journals-](https://sagepub.com/journals-permissions)
[permissions](https://sagepub.com/journals-permissions)

Abstract

Background: The ocular manifestations of the 2019 novel coronavirus disease (COVID-19) vary from acute follicular, pseudomembranous, and hemorrhagic conjunctivitis to keratoconjunctivitis with subepithelial infiltrates and dendritic lesions. Similar to other respiratory viruses, such as adenoviruses, it is thought that COVID-19 may impact the cornea. However, its impact on the cornea and anterior segment parameters are currently poorly understood.

Objective: This study aims to assess the corneal endothelial cell morphology and anterior segment parameters in patients who have recovered from COVID-19.

Methods: In this cross-sectional study, the COVID-19 group comprised 34 patients who had been diagnosed with and recovered from COVID-19, while the control group comprised age- and sex-matched individuals without any systemic or ocular diseases. The endothelial cell density (ECD), coefficient of variation (CV) of cell area, hexagonal cell percentage (HEX), anterior chamber depth (ACD), central corneal thickness (CCT), horizontal anterior chamber diameter (HACD), iridocorneal angle (ICA), horizontal visible iris diameter (HVID), pupillary diameter (PD), and keratometry values (K1 and K2) were analyzed for each participant. The differences in each of these between the groups were analyzed using either an independent samples *t* test or a Mann–Whitney *U* test based on the normality of the data.

Results: Regarding corneal endothelial cell morphology, the ECDs for the COVID-19 and control groups were 2278.50 ± 186.78 cells/mm² and 2420.15 ± 222.25 cells/mm², respectively ($p = 0.002$). A significant increase was noted in CV values in the COVID-19 group compared with the control group ($p < 0.001$). The HEX values for the COVID-19 and control groups were 56.26 ± 5.75 and 61.50 ± 3.63 , respectively ($p < 0.001$). Regarding the anterior segment parameters, no significant differences were observed between the groups ($p > 0.05$).

Conclusions: It was hypothesized that individuals who had recovered from COVID-19 would demonstrate a reduction in their endothelial functional preserves. A decrease in ECD and HEX and an increase in CV were observed in the individuals during their early post-recovery period from COVID-19.

Keywords: anterior segment, corneal endothelium, corneal topography, COVID-19, SARS-CoV-2

Received: 14 December 2021; revised manuscript accepted: 5 April 2022.

The 2019 novel coronavirus disease (COVID-19) was declared a global pandemic by the World Health Organization (WHO) on March 11, 2020, and was officially named severe acute respiratory syndrome coronavirus-2 (SARS-CoV-2).¹ While SARS-CoV-2 is known to cause substantial

pulmonary disease, it can also attack other organs throughout the body.²

Human-to-human transmission of SARS-CoV-2 mainly occurs via the inhalation of respiratory droplets expelled by an infected individual and by

Correspondence to:
Dilara Ozkoyuncu Kocabas
Department of
Ophthalmology, TOBB ETU
School of Medicine, TOBB
ETU, Ankara, Turkey.
dilaraozkoyuncu@gmail.com

Burak Oren
Department of
Ophthalmology, Adiyaman
University Training and
Research Hospital,
Adiyaman, Turkey

direct contact with contaminated surfaces.³ The ocular surface may be a transmission source via respiratory droplets or aerosolized particles that contact the surface epithelium.⁴

SARS-CoV-2 infects human hosts through the angiotensin-converting enzyme II (ACE2) receptor and the transmembrane serine protease 2 (TMPRSS2).^{5,6} ACE2 and TMPRSS2 are co-expressed in the conjunctival, limbal, and corneal epithelium as well as in the endothelial cells.⁷⁻⁹ This co-expression explains the high affinity of SARS-CoV-2 for the ocular surface and its presence in tears.

Observational and experimental studies in animals have reported that ocular infections, such as conjunctivitis, uveitis, retinitis, and optic neuritis, can be caused by beta coronaviruses.¹⁰ The currently available literature regarding ocular manifestations in COVID-19 patients in humans is primarily based on case reports; there is no other experimental evidence on these manifestations.¹¹⁻¹⁴ Case studies of acute follicular, pseudomembranous, and hemorrhagic conjunctivitis and keratoconjunctivitis with subepithelial infiltrates as the initial presentation of symptoms have been reported.^{11,12} Similar to adenoviruses, an immune-mediated mechanism composed of corneal infiltrates is present during COVID-19 infection.¹⁵

Studies have reported that COVID-19 patients experience dry eyes during their symptomatic periods. The instability of the tear film could be explained by the activity of the SARS-CoV-2 on the ocular surface epithelial cells and glands.¹⁶ In addition, corneal sensitivity could be decreased due to the corneal nerve involvement of SARS-CoV-2.¹⁵

However, there is limited data regarding retinal pathologies in COVID-19 patients, such as retinal hyper-reflective dots, microangiopathy, retinal vein occlusions, and atypical multifocal evanescent white dot syndrome.^{12,14,17} There has been only one case report of orbital myositis in a COVID-19 patient.¹⁸

Due to the expression of ACE2 in neural cells, concerns regarding the neuro-invasiveness of SARS-CoV-2 have been raised.¹⁹ Neuro-ophthalmological complications, such as optic neuropathies, cranial nerve palsies, and visual field defects, have been reported in COVID-19 patients.^{12,20}

Several viruses can impact the cornea, from the epithelium through to the endothelium. Like other respiratory viruses, such as adenoviruses and influenza viruses, SARS-CoV-2 may possess ocular tropism.^{21,22} However, few viruses are known to cause corneal endotheliitis.²³ In response to endothelial stress, corneal endothelial cells expand due to limited mitotic capacity. This compensatory mechanism results in increased cellular pleomorphism and a decreased percentage of hexagonal cells (pleomorphism) under specular microscopy.

Although the expression of ACE2 has been identified in corneal endothelial cells, and COVID-19 is known to infect humans via ACE2, there have been no reports on the corneal endothelial cells in COVID-19 under specular microscopy. Therefore, the present study was designed to assess the possible effects of COVID-19 on corneal endothelial cells and the anterior segment parameters.

Methods

Study population and design

This cross-sectional study was performed at the Department of Ophthalmology, Adiyaman University Training and Research Hospital, between October 1 and November 31, 2021. The study was conducted in accordance with the Declaration of Helsinki and was approved by the Ethics Committee of the Adiyaman University Training and Research Hospital (Approval No: 2021.10.1). All participants received oral and written study-related information, and written informed consent was obtained from each participant prior to their examination.

Patients were diagnosed with COVID-19 using a real-time reverse transcriptase-polymerase chain reaction (RT-PCR). An assay to detect respiratory specimens of SARS-CoV-2 nucleic acid was included. The examinations were performed at least 1 month after the patient returned a negative RT-PCR result. The mean time interval between the return of a negative RT-PCR test and patient examination was 38.35 ± 3.90 days (32–45).

The COVID-19 group consisted of individuals who had recovered from COVID-19 at least 30 days prior to examination. The control patients had to meet certain criteria: a normal eye examination, no history of systemic disease, and a negative RT-PCR test result.

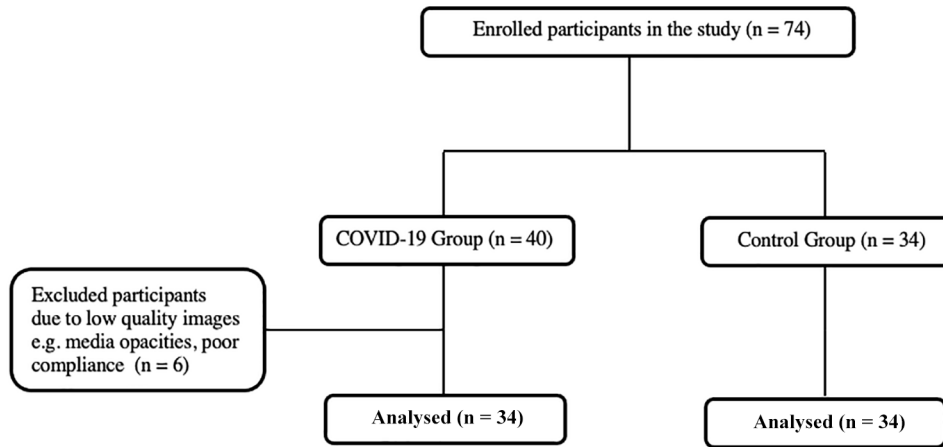


Figure 1. Flowchart for distribution of participants.

In addition, several exclusion criteria were applied to both the COVID-19 and control groups. Individuals who had myopic, hypermetropic, or astigmatic refractive errors greater than 1.0 D; used contact lenses, had corneal abnormalities, strabismus, amblyopia, uveitis, or a chronic disease, or had a history of glaucoma, ocular surgery, or ocular trauma were excluded from the study. Based on these criteria, six patients with media opacities that limited examination were excluded. Low-quality images due to poor compliance were also excluded (Figure 1).

Ocular examination protocol and measurements

All patients underwent a comprehensive ophthalmologic examination that included measurements of best-corrected visual acuity (BCVA) and intraocular pressure (IOP) (via non-contact tonometer), along with slit-lamp biomicroscopy and fundus evaluation.

Corneal endothelial cell measurements were obtained using the Nidek CEM-530 non-contact specular microscope (NIDEK Co., Ltd., Japan), which captures images of the endothelium depending on the corneal reflex. The measurements taken were endothelial cell density (ECD; cell/mm²), coefficient of variation (CV) of cell area, the percentage of hexagonal cells (HEX), and central corneal thickness (CCT). Measurements were taken when the reference line and circle were observed to be sharp on the screen. Each participant had three images taken via specular microscopy. Measurements were

taken from one image that displayed at least 100 cells with clear borders.

Anterior segment measurements were taken using the Sirius anterior segment analyzer system (Costruzione Strumenti Oftalmici, Florence, Italy), according to the manufacturer's guidelines. The CSO Sirius Topographer[®] combines two monochromatic 360° rotating Scheimpflug cameras with Placido disk topography, enabling 25 radial sections of the cornea and anterior chamber to be obtained in seconds. The system acquires keratometry measurements on a 3.0 mm diameter field of the central cornea.²⁴ The images were obtained using the automatic mode.

Several parameters were evaluated using the Sirius topography system: anterior chamber depth (ACD), horizontal anterior chamber diameter (HACD), iridocorneal angle (ICA), horizontal visible iris diameter (HVID), pupillary diameter (PD), and keratometry values (K1 and K2). The images with the best alignment and fixation were chosen for statistical analysis.

Measurements were taken consecutively in a random order. During each session, the examiner, who was masked, took each measurement three consecutive times, with a 5-min interval between each measurement. All measurements were performed under standard dim light conditions, without dilatation, and at the same time of the day (between 2 p.m. and 5 p.m.) to minimize diurnal corneal hydration variations. Before each measurement was taken, patients were instructed to blink completely to keep their eyes moist. The

Table 1. Demographic and ocular characteristics of the groups.

	Covid-19 group (n = 34)	Control group (n = 34)	p
Mean age (years)	50.1 ± 14.4	48.7 ± 9.1	0.625 ^a
Female/male	18/16	16/18	0.628 ^b
BCVA (LogMAR)	0.17 ± 0.1	0.14 ± 0.2	0.782 ^a
IOP (mmHg)	15.4 ± 2.8	15.7 ± 2.3	0.896 ^a

BCVA, best corrected visual acuity; IOP, intraocular pressure.
^aStudent *t* test.
^bChi-square test.

participants' eyes were aligned along the visual axis using a central fixation light. Measurements were only taken from the right eye of each participant.

Statistical analysis

The statistical analysis was conducted using the SPSS software (version 22; SPSS Inc., Chicago, IL, USA). Descriptive statistics were presented as mean ± standard deviations. The normality of the data was confirmed using the Shapiro–Wilk test ($\alpha = 0.05$). Categorical data were compared using the chi-square test. For comparison of the test parameters between groups, an independent samples *t* test or Mann–Whitney *U* test was used based on the normality of data. A *p* value of less than 0.05 was considered statistically significant.

Results

A total of 68 patients participated in the study; 34 patients (18 females and 16 males) comprised the COVID-19 group, and 34 age- and sex-matched healthy individuals (16 females and 18 males) comprised the control group. The demographic and ocular characteristics of both groups are displayed in Table 1. No significant difference was found in the mean age, sex distribution, mean BCVA, or intraocular pressure (IOP) between the groups ($p > 0.05$).

The corneal endothelial cell morphology and anterior segment parameters of the participants are summarized in Table 2. Regarding the corneal endothelial cell morphology, the ECD in the COVID-19 and control groups was 2278.50 ± 186.78 cells/mm² and 2420.15 ± 222.25 cells/mm², respectively ($p = 0.002$). A significant

increase was observed in the CV values of the COVID-19 group compared with the control group ($p < 0.001$). The HEX values were 56.26 ± 5.75 and 61.50 ± 3.63 , respectively ($p < 0.001$; Figure 2).

ACD, HACD, and CCT values were higher in the COVID-19 compared with the control group; however, the differences were statistically insignificant ($p > 0.05$). In terms of topographic measurements, all anterior segment parameters showed no significant difference between the groups ($p > 0.05$).

Discussion

The findings in a cohort of COVID-19 patients during their early post-recovery period (40 days after a negative RT-PCR) revealed a reduction in their endothelial functional preserves. A decrease in both ECD and HEX (pleomorphism) and an increase in CV (polymegatism) were observed in these patients' corneal endothelial cell morphologies under specular microscopy. Despite this decrease, both the ECD and HEX parameters were within the clinically normal range for both groups. However, CV was above the upper clinical parameter (0.40) in the COVID-19 group.

A wide range of ocular manifestations, including conjunctivitis, keratoconjunctivitis, dry eyes, retinal hyper-reflective dots, microangiopathy, retinal vein occlusions, atypical multifocal evanescent white dot syndrome, optic neuropathies, cranial nerve palsies, and orbital myositis, have been reported as case reports or case series in COVID-19 patients.^{11–14,17,18,20} However, whether these ocular manifestations occur as a result of the infection or its treatment has not yet been ascertained.

In addition to the main transmission routes for COVID-19, significant concern has been raised regarding potential ocular transmission.²⁵ While contaminated droplets and body fluids can easily infect the human conjunctival epithelium, it is unclear whether conjunctivitis associated with COVID-19 occurs due to primary ocular infection or the retrograde migration of viral particles from the upper respiratory tract through the nasolacrimal duct.²⁶ While some factors related to ocular infection of SARS-CoV-2 are still debated, the presence of certain receptors in the corneal endothelium of the eye means there is the potential for the virus to use the eye as a reservoir or as

Table 2. Comparison of endothelial morphology and anterior segment parameters between the groups.

	Covid-19 group (n = 34)	Control group (n = 34)	p
ECD (cell/mm ²)	2278.50 ± 186.78	2420.15 ± 222.25	0.002 ^a
CV (%)	40.31 ± 6.42	27.87 ± 4.54	<0.001 ^a
HEX (%)	56.26 ± 5.75	61.50 ± 3.63	<0.001 ^b
CCT (µm)	525.03 ± 40.02	517.82 ± 31.17	0.387 ^a
ACD (mm)	3.27 ± 0.40	3.18 ± 0.22	0.232 ^b
HACD (mm)	11.93 ± 0.65	11.80 ± 0.36	0.294 ^a
ICA (degrees)	38.14 ± 7.33	39.02 ± 4.10	0.573 ^b
HVID (mm)	12.86 ± 0.51	12.80 ± 0.40	0.560 ^a
PD (mm)	3.32 ± 0.72	3.52 ± 0.87	0.303 ^b
K1 (D)	47.89 ± 2.19	48.45 ± 1.71	0.242 ^a
K2 (D)	48.71 ± 2.36	49.07 ± 1.71	0.470 ^a

ACD, anterior chamber depth; CCT, central corneal thickness; CV, coefficient of variation of cell area; ECD, endothelial cell density; HACD, horizontal anterior chamber diameter; HEX, the percentage of hexagonal cells; HVID, horizontal visible iris diameter; ICA, iridocorneal angle; K, keratometry value; PD, pupillary diameter.

^aStudent *t* test.

^bMann–Whitney *U* test.

a connection to extraocular tissues, leading to clinical infection.²¹

ACE2 and TMPRSS2 receptors are essential for COVID-19 infection, as they facilitate SARS-CoV-2 entry into host cells.^{7,8} ACE2 and TMPRSS2 have been found in post-mortem human eye specimens, particularly in the superficial conjunctival and corneal epithelial surfaces.²⁷ Furthermore, the expression of ACE2 and TMPRSS2 receptors in the corneal endothelium has been demonstrated in both donor corneas and in human corneal epithelia obtained during refractive surgery.^{9,27}

Previous reports have documented the features of ocular surface involvement in COVID-19 patients, including bulbar conjunctiva hyperemia (alone or in association with chemosis), the follicular reaction of the palpebral conjunctiva, watery discharge, epiphora, mild eyelid edema, photophobia, burning eye, and foreign body sensation.^{12,16} Meduri *et al.*¹⁶ found that ocular symptoms worsened following the onset of COVID-19 due to alterations of the tear film. Similarly, Freni *et al.*¹⁹ found that 72% of

COVID-19 patients presented with dry eyes and displayed altered Schirmer tests and hypothesized that dry eyes were potentially related to the neuropropism of the virus.

SARS-CoV-2 can survive and replicate in the conjunctiva, even in the absence of ocular disease, and there may be viral shedding in asymptomatic patients.²⁸ Conjunctivitis has been diagnosed in numerous COVID-19 cases and, therefore, could be an early clinical feature of COVID-19.⁴

Ma *et al.*²⁹ demonstrated that SARS-CoV-2 infection has a higher affinity for the cornea compared with the conjunctiva. Despite this, the risk of COVID-19 transmission via corneal transplant is thought to be low, even in donors with COVID-19 viremia. Further fundamental studies are needed to inform evidence-based recommendations for donor selection.³⁰ The risk of viral transmission via corneal transplantation should be considered, even if the risk is low.

Cheema *et al.*¹³ demonstrated corneal involvement, specifically pseudodendritis and

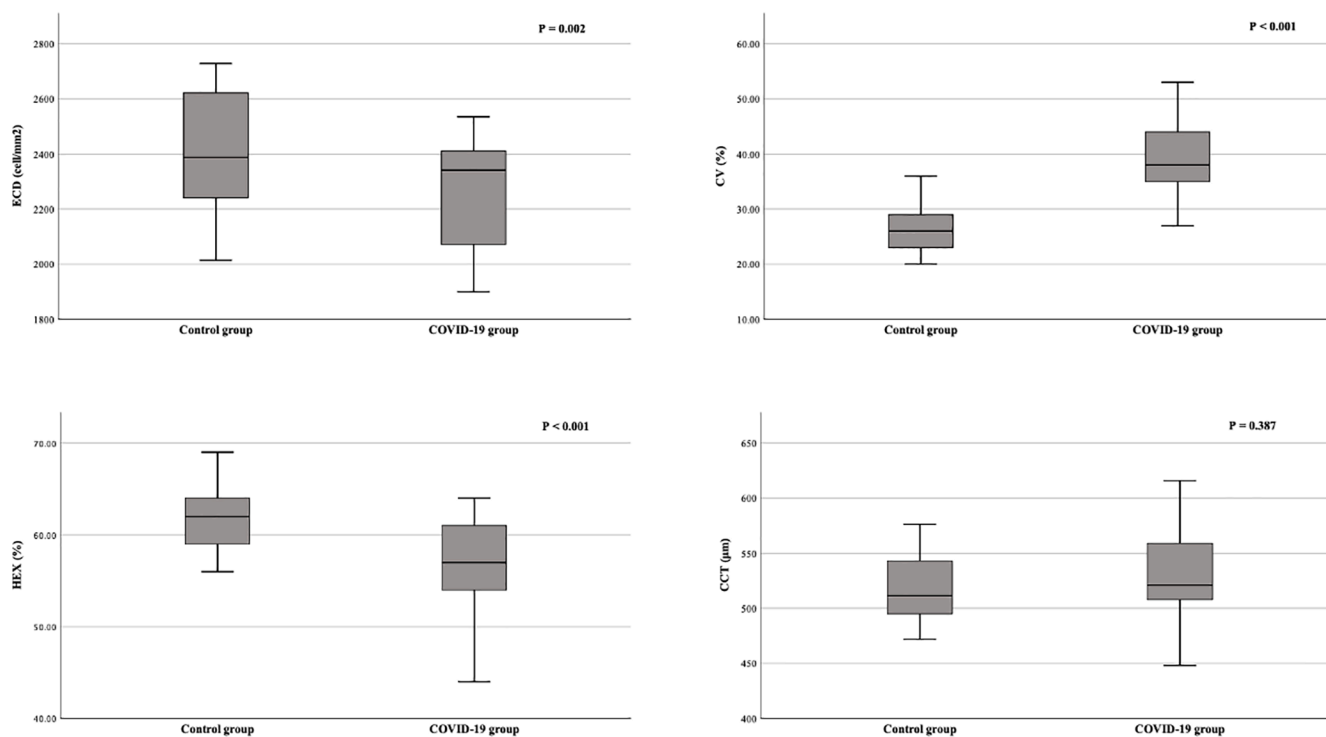


Figure 2. Box plots showing corneal endothelial cell morphology differences under specular microscopy (ECD, CV, HEX, and CCT) between the control and COVID-19 groups. A reduction in endothelial functional preserves is seen in the COVID-19 group, with a decrease in both ECD and HEX and an increase in CV ($p < 0.05$). No significant difference was found in CCT between the groups ($p > 0.05$). Error bars represent a 95% confidence interval. Outliers are identified with a small circle for minor outlier values and a star for extreme outlier values.

subepithelial infiltrates, in a COVID-19 patient whose only clinical feature was keratoconjunctivitis. Similarly, Mangan *et al.*¹⁵ presented *in vivo* confocal microscopy findings of unilateral subepithelial stromal opacities following conjunctivitis in a COVID-19 patient. The use of confocal microscopy revealed irregular corneal epithelial cells with bright borders, activated dendritic cells in the subbasal epithelial area, a notable reduction in the subbasal corneal nerve plexus, and clusters of reflective cells in the anterior stroma. However, the corneal endothelial cell layer was observed to be normal. This study highlighted that corneal infiltrates may be associated with an immune-mediated mechanism during COVID-19 infection. In addition, corneal sensitivity may be decreased as a result of corneal nerve involvement during SARS-CoV-2 infection.¹⁵ However, there is limited available data in the literature currently regarding corneal findings in patients with COVID-19.

Many types of viral pathogens, which produce the same effects under specular microscopy, induce

corneal endothelial dysfunction. Consistent with the results of the current study, this dysfunction has previously been attributed to immune dysregulation and proinflammatory effects.^{23,31} SARS-CoV-2 infection may impair the nutrition of the cornea endothelium, which receives nourishment from tears and aqueous humor.

Although human corneal endothelial cells are derived from the neural crest, they have limited regenerative capacity due to G1 phase arrest.³² Therefore, corneal endothelial cells are susceptible to damage. Damage to these cells results in a loss of transparency and visual impairment. In response to damage, remaining corneal endothelial cells enlarge and the amitotic nucleuses split. This damage can be visualized under specular microscopy as decreased ECD, with features of pleomorphism (HEX being less than 50%) and polymegethism (CV over 0.40).

Polymegethism is the first marker of endothelial dysfunction; it reflects physiological stress to the corneal endothelium and an overactive wound

repair mechanism. In the current study, a CV above 0.40 was found in the COVID-19 group. However, although lower than in the control group, ECD and HEX in the COVID-19 group remained within the normal range. Lower ECD and the temporary dysfunction of Na⁺/K⁺-ATPase pump may result in a higher CCT.³³

The current study also revealed higher ACD and HACD values in the COVID-19 group compared with the control group. However, the difference between anterior segment topography parameters was not significant between the groups. Therefore, there may be limited changes in the anterior chamber through the disruption of metabolic balance in patients with COVID-19.

The human ocular globe has its own intraocular renin-angiotensin system, both on the ocular surface and inside the eye (trabecular meshwork, aqueous humor, iris, ciliary body, non-pigmented ciliary epithelium, and retina).³⁴ One possible reason for this is that the adjacent structures may have been affected by COVID-19 infection due to the presence of receptors in the anterior chamber.

The current study investigated the impact of COVID-19 on corneal endothelial cell morphology, which had not yet been investigated in the existing literature, and demonstrated comparative data during the early post-recovery period of COVID-19 infection. Further studies on this impact will help confirm the significance of the current results.

There are some limitations to the current study. Alongside a relatively small sample size, a causal relationship between COVID-19 and corneal endothelial or anterior segment changes could not be inferred due to the study's cross-sectional nature. Large population-based cohort studies from multiple centers will be required to confirm the presence of a causal relationship. Another limitation is the possibility that some control participants may have had previously had COVID-19 but been asymptomatic and, therefore, not have had a PCR test during their infection. In the current study, the control group participants displayed no symptoms, had no history of contact with a PCR-confirmed COVID-19 patient, and returned a negative PCR prior to examination, meaning they did not have COVID-19 at the time of the study. Therefore, it was not confirmed

whether they had previously, unknowingly, had COVID-19, which may have impacted the results.

In addition, the current study only examined the early post-recovery phase of COVID-19 patients. Therefore, further research is required to explore whether these differences progress through the middle and late post-recovery phases. The strength of the current study is that it is the first to quantify the corneal endothelium and anterior segment alterations in patients with COVID-19.


In summary, the current study findings revealed an insignificant decrease in both ECD and HEX and a significant increase in the CV values of recovered COVID-19 patients during their early post-recovery period. Together, these observations highlight subtle corneal alterations that the ophthalmologist should be cautious. Therefore, follow-ups should be arranged for patients with COVID-19 to assess their susceptibility to anterior segment pathologies. Further researches are required to elucidate the ocular behavior of the virus and the clinical significance of the results.

Author contribution(s)

Burak Oren: Data curation; Supervision; Validation; Visualization; Writing – review & editing.

Dilara Ozkoyuncu Kocabas: Conceptualization; Data curation; Formal analysis; Investigation; Methodology; Resources; Validation; Writing – original draft.

ORCID iD

Dilara Ozkoyuncu Kocabas  <https://orcid.org/0000-0001-5196-0106>

Funding

The authors received no financial support for the research, authorship, and/or publication of this article.

Conflict of interest statement

The authors declared no potential conflicts of interest with respect to the research, authorship, and/or publication of this article.

Availability of data and materials


Datasets generated during and/or analyzed during the current study are available from the corresponding author on request.

References

1. Wu Z and McGoogan JM. Characteristics of and important lessons from the coronavirus disease 2019 (COVID-19) outbreak in China: summary of a report of 72 314 cases from the Chinese Center for Disease Control and Prevention. *JAMA* 2020; 323: 1239–1242.
2. Zhang Y, Geng X, Tan Y, *et al.* New understanding of the damage of SARS-CoV-2 infection outside the respiratory system. *Biomed Pharmacother* 2020; 127: 110195.
3. Singhal T. A review of coronavirus disease-2019 (COVID-19). *Indian J Pediatr* 2020; 87: 281–286.
4. Xia J, Tong J, Liu M, *et al.* Evaluation of coronavirus in tears and conjunctival secretions of patients with SARS-CoV-2 infection. *J Med Virol* 2020; 92: 589–594.
5. Mackenzie JS and Smith DW. COVID-19: a novel zoonotic disease caused by a coronavirus from China: what we know and what we don't. *Microbiol Aust.* Epub ahead of print 17 March 2020. DOI: 10.1071/MA20013.
6. Hoffmann M, Kleine-Weber H, Schroeder S, *et al.* SARS-CoV-2 cell entry depends on ACE2 and TMPRSS2 and is blocked by a clinically proven protease inhibitor. *Cell* 2020; 181: 271–280.e8.
7. Sunnak W, Huang N, Bécavin C, *et al.* SARS-CoV-2 entry factors are highly expressed in nasal epithelial cells together with innate immune genes. *Nat Med* 2020; 26: 681–687.
8. Collin J, Queen R, Zerti D, *et al.* Co-expression of SARS-CoV-2 entry genes in the superficial adult human conjunctival, limbal and corneal epithelium suggests an additional route of entry via the ocular surface. *Ocul Surf* 2021; 19: 190–200.
9. Roehrich H, Yuan C and Hou JH. Immunohistochemical study of SARS-CoV-2 viral entry factors in the cornea and ocular surface. *Cornea* 2020; 39: 1556–1562.
10. Seah I and Agrawal R. Can the coronavirus disease 2019 (COVID-19) affect the eyes? A review of coronaviruses and ocular implications in humans and animals. *Ocul Immunol Inflamm* 2020; 28: 391–395.
11. Douglas KAA, Douglas VP and Moschos MM. Ocular manifestations of COVID-19 (SARS-CoV-2): a critical review of current literature. *In Vivo* 2020; 34(3 Suppl.): 1619–1628.
12. Ho D, Low R, Tong L, *et al.* COVID-19 and the ocular surface: a review of transmission and manifestations. *Ocul Immunol Inflamm* 2020; 28: 726–734.
13. Cheema M, Aghazadeh H, Nazarali S, *et al.* Keratoconjunctivitis as the initial medical presentation of the novel coronavirus disease 2019 (COVID-19). *Can J Ophthalmol* 2020; 55: e125–e129.
14. O'Donovan C, Vyas N and Ghanchi F. Retinal vein occlusion with COVID-19: a case report and review of literature. *Ocul Immunol Inflamm.* Epub ahead of print 4 February 2022. DOI: 10.1080/09273948.2022.2032196.
15. Mangan MS, Yildiz-Tas A, Yildiz MB, *et al.* In vivo confocal microscopy findings after COVID-19 infection. *Ocul Immunol Inflamm.* Epub ahead of print 12 August 2021. DOI: 10.1080/09273948.2021.1966051.
16. Meduri A, Oliverio GW, Mancuso G, *et al.* Ocular surface manifestation of COVID-19 and tear film analysis. *Sci Rep* 2020; 10: 20178.
17. De Salvo G, Meduri A, Vaz-Pereira S, *et al.* An uncommon cold of the retina. *Surv Ophthalmol.* Epub ahead of print 22 August 2021. DOI: 10.1016/j.survophthal.2021.08.006.
18. Mangan MS and Yildiz E. New onset of unilateral orbital myositis following mild COVID-19 infection. *Ocul Immunol Inflamm* 2021; 29: 669–670.
19. Freni F, Meduri A, Gazia F, *et al.* Symptomatology in head and neck district in coronavirus disease (COVID-19): a possible neuroinvasive action of SARS-CoV-2. *Am J Otolaryngol* 2020; 41: 102612.
20. Gold DM and Galetta SL. Neuro-ophthalmologic complications of coronavirus disease 2019 (COVID-19). *Neurosci Lett* 2021; 742: 135531.
21. Belser JA, Rota PA and Tumpey TM. Ocular tropism of respiratory viruses. *Microbiol Mol Biol Rev* 2013; 77: 144–156.
22. Belser JA, Lash RR, Garg S, *et al.* The eyes have it: influenza virus infection beyond the respiratory tract. *Lancet Infect Dis* 2018; 18: e220–e227.
23. Moshirfar M, Murri MS, Shah TJ, *et al.* A review of corneal endotheliitis and endotheliopathy: differential diagnosis, evaluation, and treatment. *Ophthalmol Ther* 2019; 8: 195–213.
24. Wang Q, Savini G, Hoffer KJ, *et al.* A comprehensive assessment of the precision and agreement of anterior corneal power measurements obtained using 8 different devices. *PLoS ONE* 2012; 7: e45607.
25. Li JO, Lam DSC, Chen Y, *et al.* Novel coronavirus disease 2019 (COVID-19): the importance of recognising possible early ocular

- manifestation and using protective eyewear. *Br J Ophthalmol* 2020; 104: 297–298.
26. Lu CW, Liu XF and Jia ZF. 2019-nCoV transmission through the ocular surface must not be ignored. *Lancet* 2020; 395: e39.
 27. Zhou L, Xu Z, Castiglione GM, *et al.* ACE2 and TMPRSS2 are expressed on the human ocular surface, suggesting susceptibility to SARS-CoV-2 infection. *Ocul Surf* 2020; 18: 537–544.
 28. Liang L and Wu P. There may be virus in conjunctival secretion of patients with COVID-19. *Acta Ophthalmol* 2020; 98: 223.
 29. Ma D, Chen CB, Jhanji V, *et al.* Expression of SARS-CoV-2 receptor ACE2 and TMPRSS2 in human primary conjunctival and pterygium cell lines and in mouse cornea. *Eye (Lond)* 2020; 34: 1212–1219.
 30. Casagrande M, Fitzek A, Spitzer MS, *et al.* Presence of SARS-CoV-2 RNA in the cornea of viremic patients with COVID-19. *JAMA Ophthalmol* 2021; 139: 383–388.
 31. Jin SX and Juthani VV. Acute corneal endothelial graft rejection with coinciding COVID-19 infection. *Cornea* 2021; 40: 123–124.
 32. Joyce NC, Navon SE, Roy S, *et al.* Expression of cell cycle-associated proteins in human and rabbit corneal endothelium in situ. *Invest Ophthalmol Vis Sci* 1996; 37: 1566–1575.
 33. Lundberg B, Jonsson M and Behndig A. Postoperative corneal swelling correlates strongly to corneal endothelial cell loss after phacoemulsification cataract surgery. *Am J Ophthalmol* 2005; 139: 1035–1041.
 34. Holappa M, Vapaatalo H and Vaajanen A. Many faces of renin-angiotensin system – focus on eye. *Open Ophthalmol J* 2017; 11: 122–142.

Visit SAGE journals online
[journals.sagepub.com/
 home/oed](https://journals.sagepub.com/home/oed)

 SAGE journals